
RESENTING CLINICAL SIGNS
DATE

History: History of degenerative valve disease and urinary bladder TCC. Now experiencing syncopal episodes. ECG – sinus tachycardia. Receiving pimobendan 2.5 mg BID, lisinopril 5 mg BID, piroxicam 3 mg QD, gabapentin 50 mg BID.

10/11/21

ECHOCARDIOGRAPHIC FINDINGS
PERFORMED BY:

2D, M-mode, and Doppler study.

 Pamela Harrigan,
 RDCS

There is severe left atrial dilation. The mitral valve leaflets are thickened and exhibit systolic prolapse. A severe jet of eccentric mitral regurgitation is present. There is severe left ventricular dilation. Left ventricular systolic function is hyperdynamic. The aorta and aortic valve are normal. Right atrial and right ventricular dimensions are normal. The tricuspid valve leaflets are mildly thickened, and a mild jet of tricuspid regurgitation is present. TR velocity is consistent with the presence of moderate pulmonary hypertension (PG 56 mmHg). The pulmonary artery and pulmonic valve are normal. No pericardial effusion or cardiac masses are seen.

INTERPRETED BY

 Keith Blass, DVM,
 MS, DACVIM
 (Cardiology)

LA – 51.0 mm

LA/Ao – 2.77

PATIENT

LVIDd – 47.3 mm

LVIDs – 21.3 mm

Libby Engel

FS – 55%

LVOT – 1.08 m/s

RVOT – 0.53 m/s

SPECIES

TR – 3.74 m/s

Canine

ASSESSMENT/RECOMMENDATIONS

Degenerative mitral and tricuspid valve disease

Pulmonary hypertension

BREED

Poodle Mix

This examination demonstrates some progression of Libby's mitral valve disease over the past year, as she now has severe secondary dilation of both her left atrium and left ventricle, as well as moderate secondary pulmonary hypertension. Both Libby's mitral valve disease and pulmonary hypertension are advanced enough to be able to result in syncope, therefore, one or both diseases is likely contributing to Libby's episodes, though an intermittent arrhythmia should be considered as well. Libby's risk for the development of left-sided congestive heart failure is high, therefore, careful monitoring of her respiratory rate/effort is recommended.

SEX

FS

Libby's tricuspid valve disease is mild and appears to be well-compensated.

AGE

12 y

Given the changes seen in this exam, I recommend adding sildenafil (10 mg TID) to Libby's current therapy with pimobendan and lisinopril, as this medication should reduce the severity of her pulmonary hypertension.

WEIGHT

24.6 lb

A Holter and/or event monitor is recommended if Libby continues to experience syncopal episodes.

HOSPITAL NAME

A recheck echocardiogram is recommended in 6 months. Thoracic radiographs are recommended if clinical signs compatible with congestive heart failure develop.

Wood River AH

REFERRING VET

Dr. Fischer



DATE

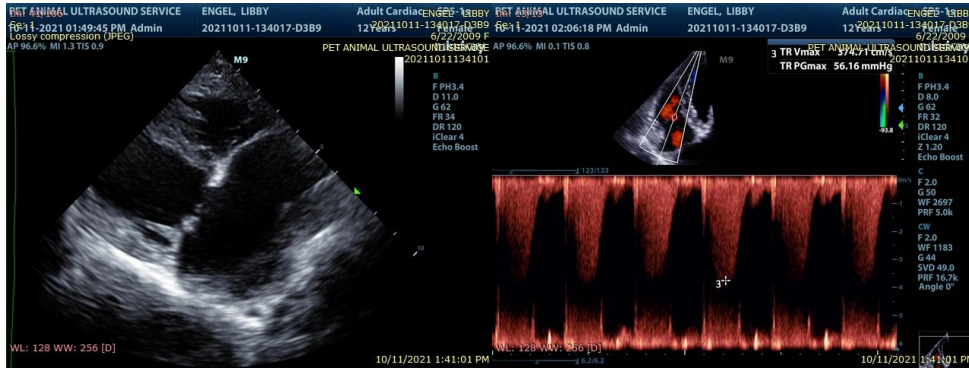
10/11/21

PERFORMED BY:

Pamela Harrigan,
RDMS

INTERPRETED BY

Keith Blass, DVM,
MS, DACVIM
(Cardiology)



The information and recommendations provided are based on the images presented by the referring veterinarian. No evaluation can be communicated regarding pathology that was not visible in the image/video clips provided.

Thank you for this referral. If the clinical or image interpretation does not parallel your findings or if I can be of any further assistance please contact me.

PATIENT

Libby Engel

Keith Blass, DVM, MS, DACVIM (Cardiology)
KeithBlass@gmail.com
631-804-5754

SPECIES

Canine

BREED

Poodle Mix

SEX

FS

AGE

12 y

WEIGHT

24.6 lb

HOSPITAL NAME

Wood River AH

REFERRING VET

Dr. Fischer